Chapter 29

Laparoscopic Surgery for Tubal Block and Hydrosalpinx

Chapter 29 : Laparoscopic Surgery for Tubal Block and Hydrosalpinx

There are several surgeries that can be performed for tubal block and hydrosalpinx.

Hydrosalpinx

A hydrosalpinx is usually associated with adhesions around the tube. The tube may be adherent to the ovary, an ovarian cyst, uterus or pelvic side walls. These adhesions are usually released and the tubes detached before proceeding with the surgery. The 2 surgeries that can be offered for hydrosalpinx are as follows:

1. Removal of the fallopian tube (salpingectomy).

Generally this is a simple operation that can be performed laparoscopically. The difficulty is to release the tube from its adhesion to the pelvic and abdominal organs. Once it is released the tube can be excised easily with the use of diathermy and scissors. Usually the whole tube is removed up to the cornual end.

Scan Me

Watch Video 29.1
Laparoscopic bilateral salpingectomy for bilateral hydrosalpinx

http://vimeo.com/150044052

Case 29.1 : Bilateral hydrosalpinx laparoscopic bilateral salpingectomy done followed by 2 successful IVF cycles

RN consulted me in May 2008 with a history of subfertility for 7 years. Hysterosalpingogram done in another country, showed bilateral hydrosalpinx. After discussing the advantages and disadvantages of salpingectomy she underwent a laparoscopic bilateral salpingectomy. She underwent an IVF cycle in August 2008. It was a successful cycle and she delivered a baby boy in 2009. She underwent a second IVF cycle in 2014 and is currently pregnant.

Discussion

When there is gross hydrosalpinx, performing laparoscopic salpingectomy before IVF/ICSI increases the chances of pregnancy.

2. Fimbrioplasty (opening and creating the fimbrial end of the tube)

Adhesiolysis is done to release the tube. To ensure that there is no block at the cornual end, methylene blue dye is injected and the hydrosalpinx should be filled with the dye. A cruciate incision is made at the most distal end of the tube.

Scan Me

Watch Video 29.2
Laparoscopic bilateral fimbrioplasty for bilateral hydrosalpinx

http://vimeo.com/150044057

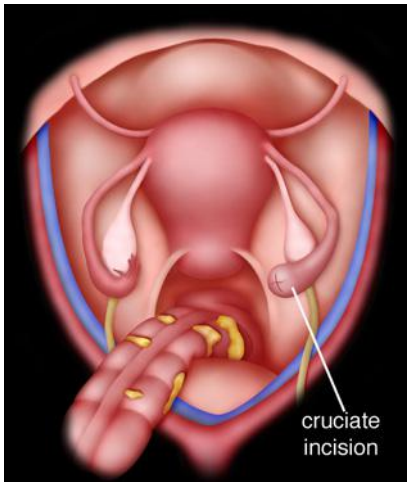

Figure 29.1
Cruciate incision made on the right hydrosalpinx

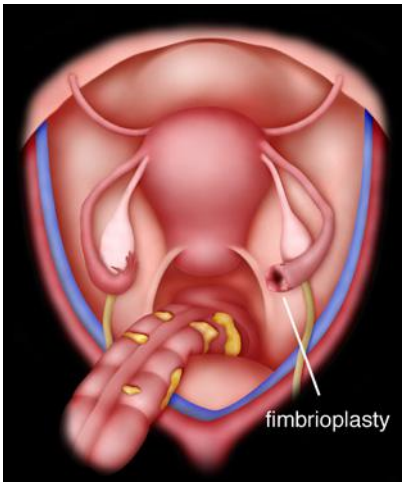

Figure 29.2 Fimbrioplasty done

The fluid in the tube is then removed. The ends of the tube are sutured using fine sutures to evert it (turned it out) and attach it to the outside of the tube, so as to keep it open and prevent it from closing back after the surgery. Suturing using fine sutures also requires advanced laparoscopic skills. Once the tube is repaired, it is tested to see whether it is patent.

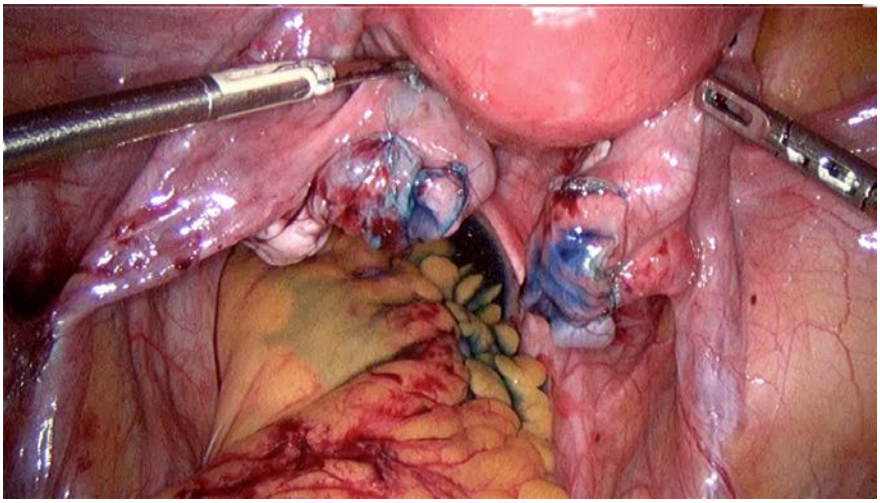

Figure 29.3 Completed Bilateral Fimbrioplasty

Controversy In Surgery for Hydrosalpinx

Hydrosalpinx is the presence of fluid in a fallopian tube its cavity and blockage of the tube at the fimbrial end. Chronic presence of fluid in the tube can lead to damage of the cilia in the tube. Damaged cilia will decrease the function of the fallopian tube in moving eggs and sperm. The larger the hydrosalpinx, the more the damage done to the inner lining and cilia of the fallopian tube.

Another problem with a hydrosalpinx is that, fluid collected in the tube can flow into the endometrial cavity. This fluid can also prevent embryo implantation during natural conception when the other tube is patent and normal. In IVF, when an embryo is placed in the uterine cavity, this fluid can wash away the embryos preventing implantation.

The surgical management of hydrosalpinx is controversial. If the hydrosalpinx is large especially if it can be seen on ultrasound, then removal of the tube is the best surgery. If it is bilateral, both the tubes have to be removed and the patient will then require IVF to conceive.

If the hydosalpinx is small and only detected during hysterosalpingography (HSG), then there is difficulty in deciding which is the best surgery for the patient. If the hydrosalpinx is in only one tube, the tube can be removed and the patient can conceive naturally with the other normal tube, without the worry that the fluid in the tube with hydrosalpinx will interfere with her chances of pregnancy.

If the hydrosalpinx is bilateral then a decision has to be made whether to repair the tube by fimbrioplasty or remove both the tubes. This decision can be an emotional one. On the other hand, the advantage of removal of the tube is that the patient's chances of pregnancy after IVF will probably improve but the disadvantage is that, she will never be able to conceive naturally. The advantage of fimbrioplasty is that by repairing the tube, the patient still has a chance of conceiving naturally, but the disadvantage is that if she does not conceive and if the hydosalpinx recurs she may need another surgery to remove the tube before undergoing IVF.

Tubal block

When the tube is blocked either at the cornual end or midway within the tube, such block may be due to spasm or adhesions within the tube. Tubal insufflation is usually done by placing a cannula in the cavity and closing off the cervix and then pushing fluid with dye into the cavity, to open up and flush the tube. When no dye is seen coming out of the fimbrial end, several things can be done.

1) A small tube can be placed directly at the tubal ostium (g) and dye can be injected to "open up the tube".

2) A solid wire can be passed via the catheter placed at the tubal ostium and the wire can then be pushed to assist in releasing any adhesions within the tube to open it up (see chapter 40 and Figures 40.5, 40.6 and 40.7).

3) Reimplantation of the tube into the cornual end of the uterus. Occasionally, the block is in the cornual end of the tube. In such situation, the blocked area in the cornual end can be excised and the tube detached from the uterus and then reimplanted into the patient's cornual end. This surgery was popular before the advent of IVF, However, it is now rarely done because it is a difficult surgery to perform and the pregnancy rates are not very high. In such situations IVF is advised.

All these strategies can assist in opening up the tube in some patients but there is no guarantee that the "opened tube" will be functional or the patient be able to conceive spontaneously after the surgery. Tubes that are "opened" during laparoscopic surgery may close back after the surgery. If the patient could not conceive spontaneously, then a repeat HSG should be performed. If the tubes are blocked again, then she may require IVF. (watch Video 29.3 Hysteroscopic cannulation for proximal tubal block)

Scan Me

Watch Video 29.3
Hysteroscopic Cannulation
for Proximal Tubal Block

https://vimeo.com/150044067

Summary

Tubal block and hydrosalpinx are not uncommon among women who have difficulty in conceiving. These conditions are usually diagnosed by a hysterosalpingogram (HSG). Tubal block may be "opened up" by performing a laparoscopy and a hysteroscopy at the same time. Hydrosalpinx can be either repaired (fimbrioplasty) or removed (salpingectomy). In many patients with these conditions, IVF may have to be done to achieve a successful pregnancy.